Kidney – Ectopic Tissue

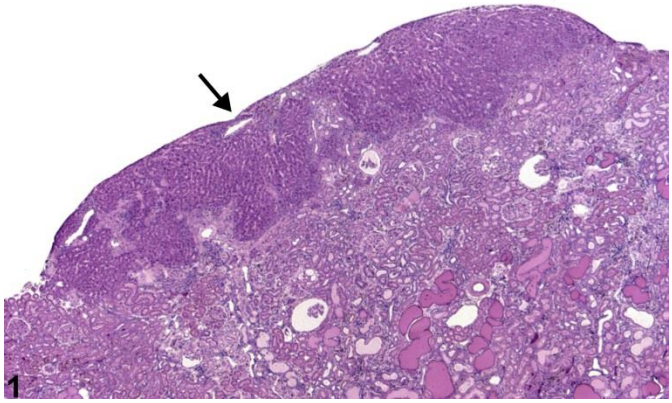

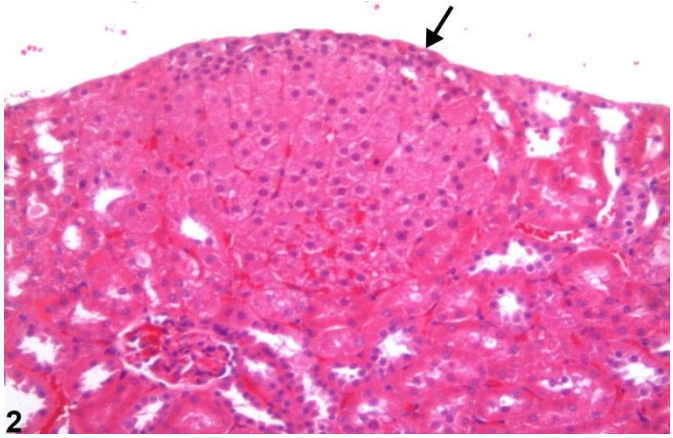

Figure Legend: Figure 1 Kidney - Ectopic tissue, Liver in a female F344/N rat from a chronic study. Ectopic liver (arrow) involves the capsule of the kidney. **Figure 2** Kidney - Ectopic tissue, Adrenal gland in a young Sprague-Dawley rat. A well-demarcated subcapsular lesion (arrow) is diagnosed as an ectopic adrenal gland. (Image provided courtesy of Dr. Johnson Thomas, Dow Chemical USA.)

Comment: In rare cases, various foci of extrarenal tissue can be noted in the kidney, particularly near the capsule. Liver tissue and adrenal tissue have been reported (Figure 1 and Figure 2). These ectopic tissues occur spontaneously with no pathologic or toxicologic significance. They must be differentiated from the presence of either primary or metastatic neoplasia.

Recommendation: Ectopic tissues should be diagnosed when present but should not be graded. The diagnosis should be modified with the tissue of origin (e.g., Kidney - Ectopic tissue, Liver).

References:

Frazier KS, Seely JC, Hard GC, Betton G, Burnett R, Nakatsuji S, Nishikawa A, Durchfeld-Meyer B, Bube A. 2012. Proliferative and non-proliferative lesions in the rat and mouse urinary system. Toxicol Pathol 40:14S-86S.
Abstract: http://www.ncbi.nlm.nih.gov/pubmed/22637735

Prentice DE, Jorgenson W. 1979. Ectopic adrenal tissue in the kidney of rhesus monkeys (*Macaca mulatta*). Lab Anim 13:221-223.
Full-text: http://lan.sagepub.com/content/13/3/221.full.pdf

Kidney – Ectopic Tissue

Authors:

John Curtis Seely, DVM, DACVP
Senior Pathologist
Experimental Pathology Laboratories, Inc.
Research Triangle Park, NC

Amy Brix, DVM, PhD, DACVP
Senior Pathologist
Experimental Pathology Laboratories, Inc.
Research Triangle Park, NC