Testis – Amyloid

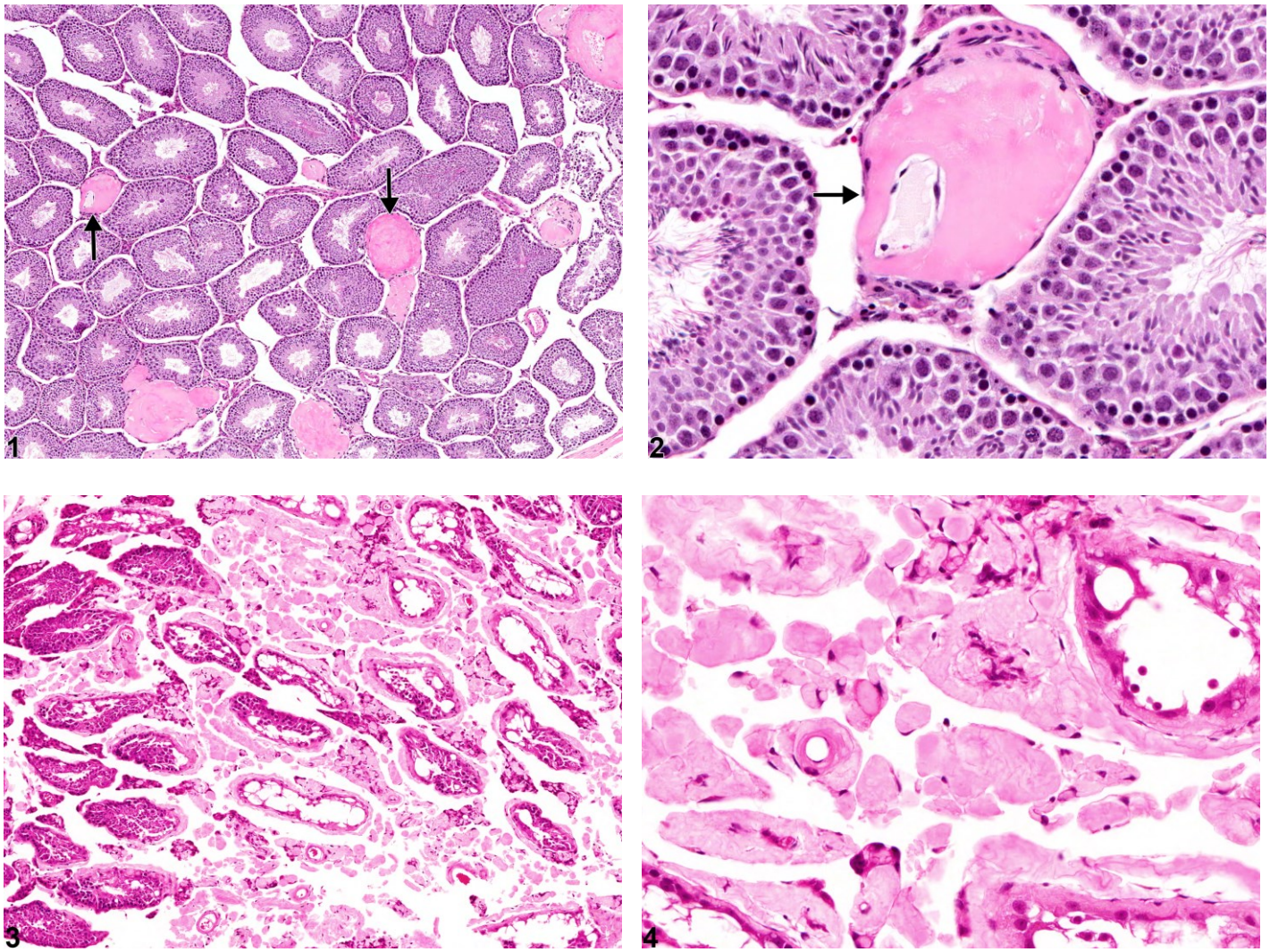

Figure Legend: Figure 1 Testis - Amyloid in a male B6C3F1 mouse from a chronic study. There are perivascular accumulations of hemogenous, eosinophilic material in the interstitium (arrows). **Figure 2** Testis - Amyloid in a male B6C3F1 mouse from a chronic study. Higher magnification of Figure 1 with perivascular accumulation of amyloid (arrow). **Figure 3** Testis - Amyloid in a male Swiss CD-1 mouse from a chronic study. Widespread accumulation of amyloid with secondary tubular degeneration and necrosis. **Figure 4** Testis - Amyloid in a male Swiss CD-1 mouse from a chronic study. Higher magnification of Figure 3 showing extensive amyloid deposition.

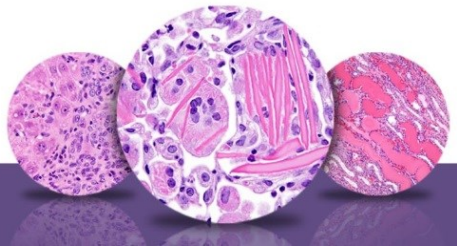

Testis – Amyloid

Comment: Testicular amyloid consists of extracellular accumulation of homogeneous, eosinophilic and amorphous material in the interstitium (arrows, Figure 1 and Figure 2). When stained with Congo red, the material emits a green birefringence with polarized light. Amyloid can be focal or multifocal (Figure 1 and Figure 2) or diffuse (Figure 3 and Figure 4) and is generally bilateral in distribution. The amyloid may be deposited loosely within the interstitial space (Figure 3) or accumulate within the vascular walls (Figure 2) or within the peritubular myoid cell layer (Figure 4). In severe cases, the parenchyma is effaced and the remnants of atrophic tubules are widely separated by clumps of amyloid. Amyloid deposition may be localized (involving only one organ) or, more commonly, systemic (involving several organ systems).

Recommendation: Whenever present, amyloid should be diagnosed and graded and should be discussed in the pathology narrative if the incidence and/or severity appears to be related to chemical administration. Bilaterality should be indicated in the diagnosis if present. Associated lesions such as germ cell degeneration or germinal epithelium atrophy should not be diagnosed separately unless warranted by their severity, but should be described in the narrative.

References:

Creasy D, Bube A, de Rijk E, Kandori H, Kuwahara M, Masson R, Nolte T, Reams R, Regan K, Rehm S, Rogerson P, Whitney K. 2012. Proliferative and nonproliferative lesions of the rat and mouse male reproductive system. Toxicol Pathol 40:40S-121S.
Abstract: http://www.ncbi.nlm.nih.gov/pubmed/22949412

Gordon LR, Majka JA, Boorman GA. 1996. Spontaneous nonneoplastic and neoplastic lesions and experimentally induced neoplasms of the testes and accessory sex glands. In: Pathobiology of the Aging Mouse, Vol 1 (Mohr U, Dungworth DL, Capen CC, Carlton WW, Sundberg JP, Ward JM, eds). ILSI Press, Washington, DC, 421-441.
Abstract: http://catalog.hathitrust.org/Record/008994685

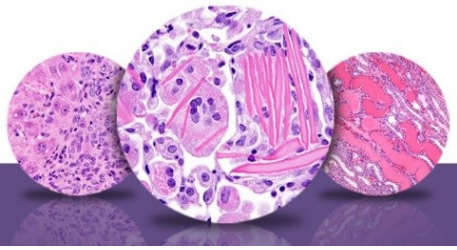

Testis – Amyloid

Authors:

Dianne M. Creasy, PhD, Dip RCPath, FRCPath
Dianne Creasy Consulting LLC
Pipersville, PA

Robert R. Maronpot, DVM, MS, MPH, DACVP, DABT, FIATP
Senior Pathologist
Experimental Pathology Laboratories, Inc.
Research Triangle Park, NC

Dipak K. Giri, DVM, PhD, DACVP
Toxicologic Pathologist
Integrated Laboratory Systems, Inc.
Research Triangle Park, NC